



UT Health
San Antonio
School of Dentistry



DENT ECHO
presents:
Today I am Treating a Person who has Autism -A Social Story about Autism for Dental Professionals-

DATE
Thursday
March 21, 2024

TIME
12 - 1pm
CST

REGISTER NOW

ZOOM REGISTRATION

Free CDE Credit Registration
*Supercode: Echo2024

Didactic Presented by:
Jennifer Farrell, DDS, DABSCD
UT Health San Antonio
School of Dentistry
Phil & Karen Hunke Special Care Clinic
Director

Case Presented by:
Claudia I Contreras, DDS
UT Health San Antonio
School of Dentistry
Assistant Professor/Clinical
Department of Developmental Dentistry

Learn more about DENT ECHO at:
<https://wp.uthscsa.edu/echo/dent/>

UT Health
San Antonio
School of Dentistry

TACHC
Texas Association of Child and Adolescent Health Care

ECHO

TODAY I AM TREATING A PERSON WHO HAS AUTISM

- A SOCIAL STORY ABOUT AUTISM FOR DENTAL PROFESSIONALS -

JENNIFER FARRELL, DDS, DABSCD



TODAY I WILL SEE A NEW PATIENT NAMED OZZIE. MY ASSOCIATE WILL SEE HIS SISTER, HARRIET. THEY BOTH HAVE AUTISM.

I am not sure I am qualified to manage this patient...

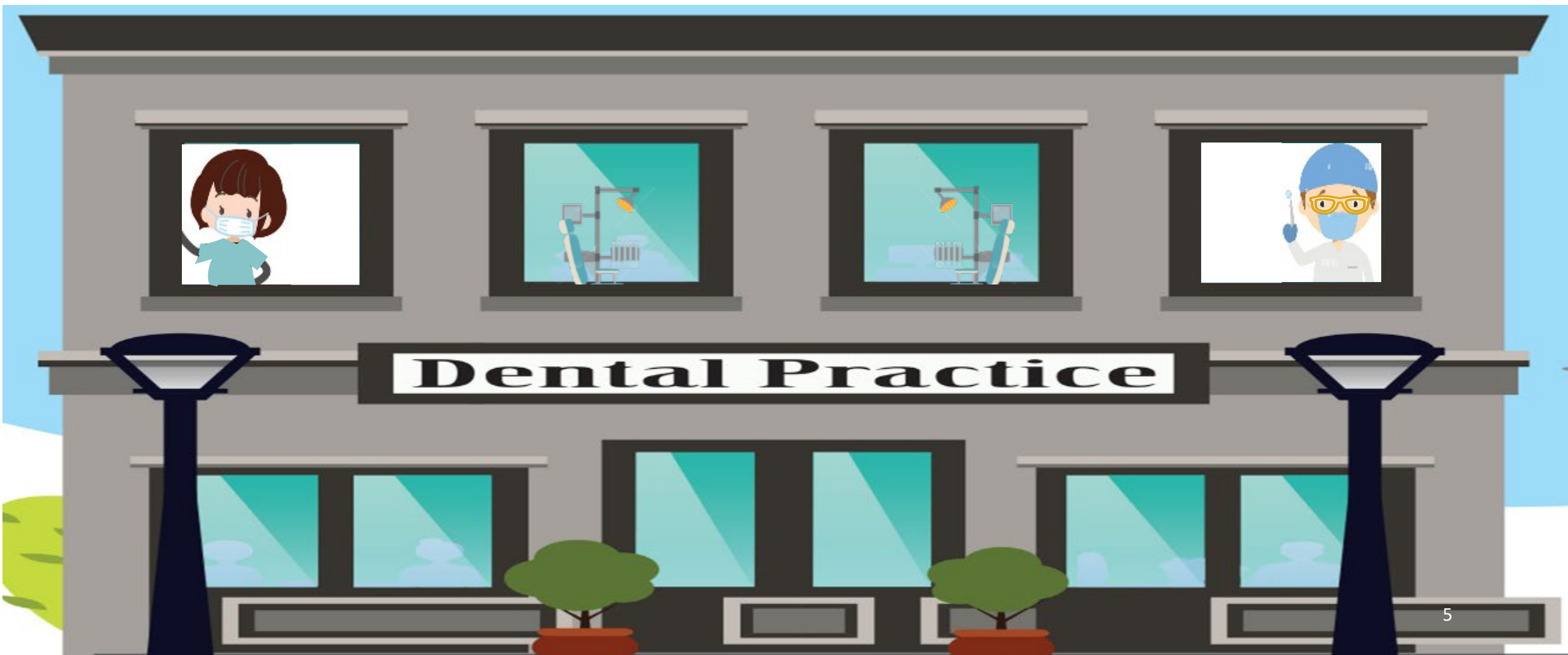I may just refer this patient for IV sedation...

Dental Practice

Ozzie and Harriet arrive a few minutes late. Harriet did not expect the change her in routine and had a meltdown during the ride to the office.



My colleague and I put on our PPE. We do not hear any noise from the waiting room. We are relieved. We are ready to see Ozzie and Harriet.



OZZIE IS FIRST. HE BECOMES AGITATED WHEN HE HEARS HIS NAME. HE DOES NOT WANT TO ENTER THE TREATMENT AREA. I DO NOT WANT TO ENTER THE TREATMENT AREA. I THINK "I AM NOT TRAINED TO TREAT PATIENTS WITH AUTISM". I BEGIN TO FILL OUT THE REFERRAL FORM.



WHEN I RETURN WITH THE REFERRAL, I SEE MY ASSISTANT SITTING ON THE FLOOR WITH OZZIE. HE IS CALM AS SHE EXPLAINS EACH STEP TO HIS TREATMENT. SHE LETS HIM KNOW THAT TO EARN A PRIZE, HE MUST DO EACH STEP - OZZIE DECIDES TO COME IN.



OZZIE SAT ON THE GUEST CHAIR AND OPENED HIS MOUTH. I THOUGHT I'D JUST TRY TO GET A QUICK PEEK, BUT HE LET ME DO A COMPLETE EXAM AND EVEN ALLOWED FOR AN XRAY! AFTER A BREAK, HE LET ME REMOVE THE CALCULUS AROUND HIS SORE TOOTH!



ozzie earned HIS PRIZE TODAY and SO DID I!



MEANWHILE, HARRIET HAS BEEN WAITING IN THE NEXT ROOM. MY ASSOCIATE ASKS HARRIET WHICH COLOR TOOTHBRUSH SHE WANTS HER TO USE. HARRIET CHOOSES PURPLE.




JUST AS MY ASSOCIATE BEGINS, HARRIET SUDDENLY BECOMES VERY UPSET. SHE SQUIRMS AND CRIES UNCONTROLLABLY. HARRIET'S MOTHER TAKES HER TO THE BATHROOM FOR A BREAK.



WHEN HARRIET COMES OUT OF THE BATHROOM, SHE IS HAPPY. YOU DON'T WANT TO UPSET HER AGAIN, SO YOU DECIDE TO REFER HER FOR SEDATION BUT...



HARRIETT HAPPILY RETURNS TO THE OPERATORY ON HER OWN...



... HOPS RIGHT INTO THE CHAIR AND OPENS HER MOUTH...SHE IS A GREAT PATIENT! YOU THINK, TREATING SOMEONE WITH AUTISM IS NOT THAT DIFFERENT FROM TREATING ANYONE ELSE.



TODAY I SAW A PATIENT NAMED OZZIE. MY ASSOCIATE SAW HIS SISTER, HARRIET. THEY BOTH HAVE AUTISM. WE CAN'T WAIT TO SEE THEM IN 6 MONTHS.

Hmmm- so she just needed to use the bathroom..

Hmmm- he just needed time to know the routine

Dental Practice

Take HOME GOODIES

Those who have Autism face challenges with communication, behavior, and restrictiveness.

Predictable routines help people who have Autism to better cope with their environment.

Visual aids can help to outline the steps to the procedure, the expectations, and the endpoint

Treatment does not have to be done in the dental chair.

Breaks not only help the patient but also, the providers.

Only give positive reinforcement for met expectations.

Tailor approach for each patient.

Remember that behavior is a form of communication.

Addressing sensory needs, countdowns and visuals can provide comfort.

Dental findings are generally related to maladaptive behaviors and restrictiveness.



I hope this is on my schedule again tomorrow!



My dentist sure can throw a ball!

Questions?



Case Presentation

Join by Web PollEv.com/ccontreras247 Join by Text Send **ccontreras247** to **37607**



Start the presentation to see live content. For screen share software, share the entire screen. Get help at pollv.com/app



Do you treat autistic patients?

(A) No




(B) Yes



What age group do you treat? (you can select multiple options- by adding space or comma between the selected options)


(A) 0 to 6 yrs



(B) 7 to 12 yrs



(C) 13 to 17yrs



(D) 18yrs and above



(E) None of the above



CASE 1

Patient Introduction

Age: 7 year old currently (at time of evaluation was 3 years old)

Gender: female

Chief complaint: Is here for evaluation of cavities. Second opinion.

Review of medical & dental history

MEDICAL

- ASA 2
 - Autistic
 - Eczema
- Meds
 - Steroid cream
- Other:
 - Hx of occupational therapy
 - Speech therapy

DENTAL

- Visit on Oct/2019 for evaluation
 - Was told patient had 2 cavities
 - Knee to knee exam completed and able to use explorer; used bubbles as distraction



Dental Recall Exam



3 years old at this visit on 7/2020

- FINDINGS: tooth C (facial) cavitation is beginning, tooth H (facial) cavitation is beginning, tooth B (occlusal) stick

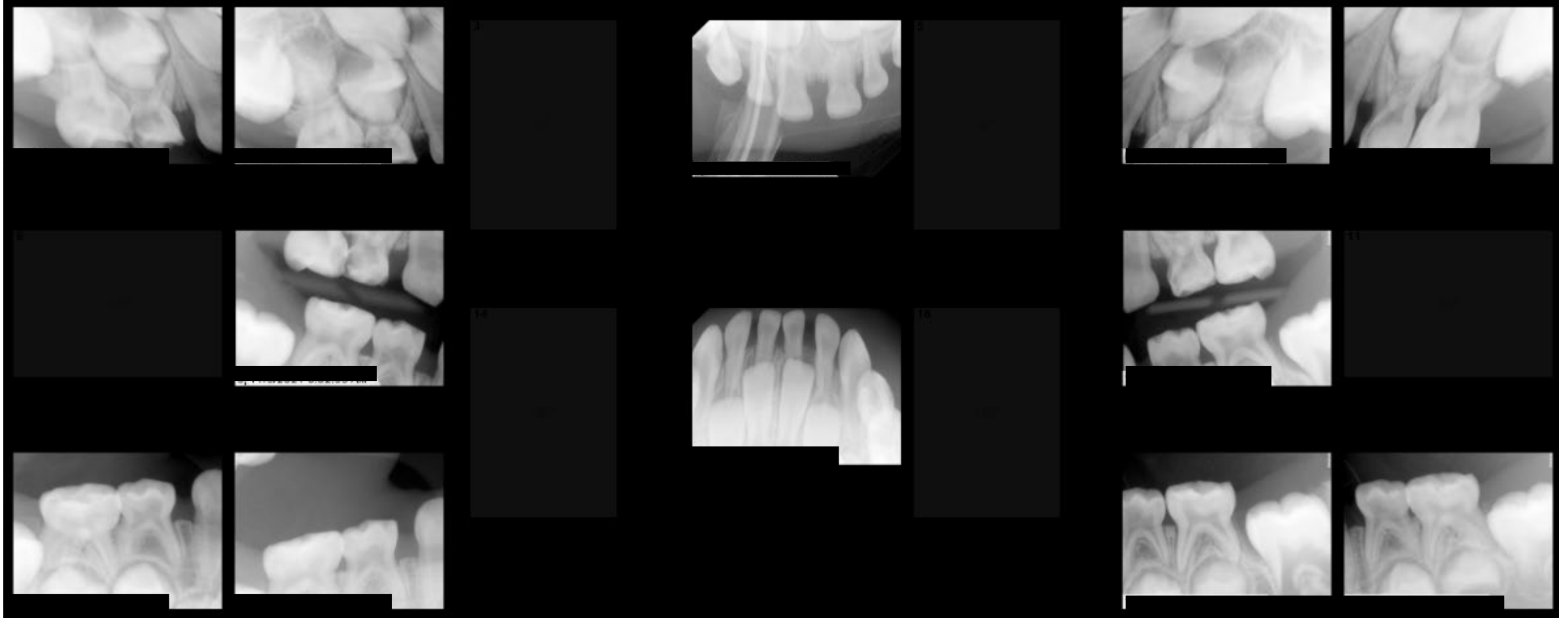
Treatment recommended: SDF application to C and H. Tooth B- interim therapeutic restoration using glass ionomer; knee to knee and no use of papoose

**Able to maintain from caries progression Tooth B,C and H.

Treatment Completed under GA

D2330	F	L	C
D2330	M	F	C
D2331	G	FL	C
D2930	A	MODBL	C
D2930	B	MODBL	C
D2930	C	MIDFL	C
D2930	H	MIDFL	C
D2930	I	MODBL	C
D2930	J	MODBL	C
D2930	T	MODBL	C
D2930	S	MODBL	C
D2930	L	MODBL	C
D2930	K	MODBL	C
D3220	B		C

Referred to General Anesthesia for FM DR

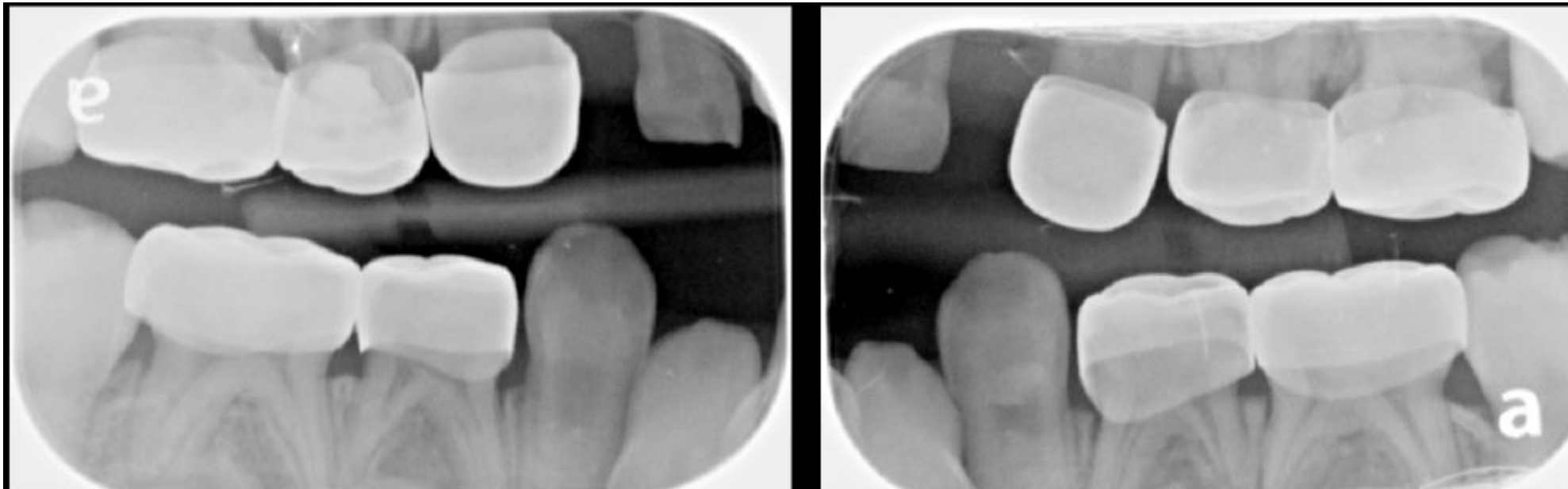


Recare...

- Recall appt after dental rehab was 5/2022 (patient is now 5 years old)
 - Now is talkative, sat in chair and allowed exam and toothbrush prophylaxis
 - DID NOT LIKE FLUORIDE
 - Restorations intact
- Recall appt 12/2022 (patient is now 6 years old)
 - Restorations intact
 - Behavior is better; sat in dental chair; allowed the use of suction

Recare...

- Recall appt 8/2023
 - More talkative, inquisitive (asking lots of questions); is now reading!
 - Allowed x-rays (1st time in clinic)- 2bw's taken
 - Incipient lesion on #19(buccal), informed mother and monitoring.



Exam (talk
about
vitamins)

Flossing



CASE 2

Patient Introduction

Age: 7 year old currently (at time of initial exam was 5 years old)

Gender: male

Chief complaint: Patient was to have FMDR under general anesthesia and was unable to have treatment completed due to finances.

Review of medical & dental history

MEDICAL

- ASA 2
 - Autistic: speech delay and diagnosed at age 3
- Meds
 - none
- Other:
 - Speech therapy

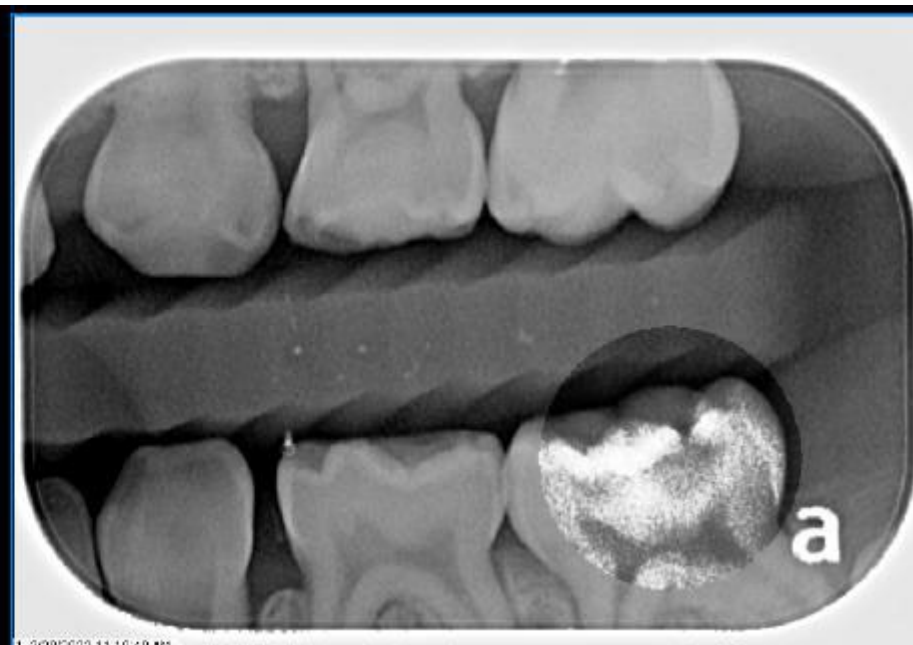
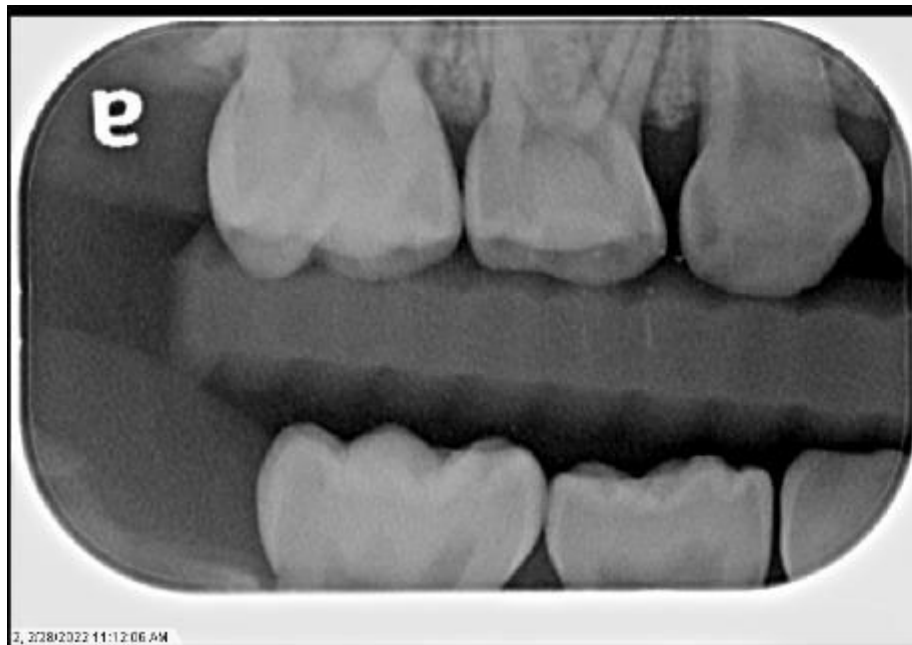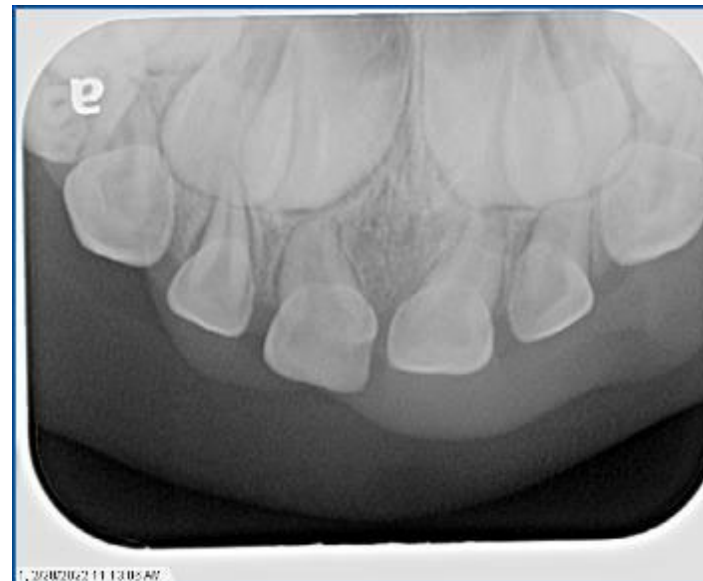DENTAL

- Visit on 2/2022 for initial evaluation
 - Treatment alternative was SDF of teeth: J,K
 - OBTAINED x-rays
- Recall visit on 9/2022
 - Patient sat in chair, on his left side but reluctant
 - Unable to get x-rays

Note on Behavior

- Patient screaming and crying when brought back from lobby. Patient refused to sit and chair and exhibited combative behavior. Patient walked into OR chief room while provider was talking to mother. Patient allowed Dr. Shin to do oral evaluation **while standing**. With Dr. Shin's assistant was able to get x-rays. **Mother states this is the first time patient allowed x-rays**. Using a lot of TSD Dr. Y Perez performed prophylaxis but patient would not allow toothpaste in his mouth. Mother states patient has an oral aversion and hates toothpaste. The patient loves dinosaurs and has a green T-rex that he brought to the appointment.

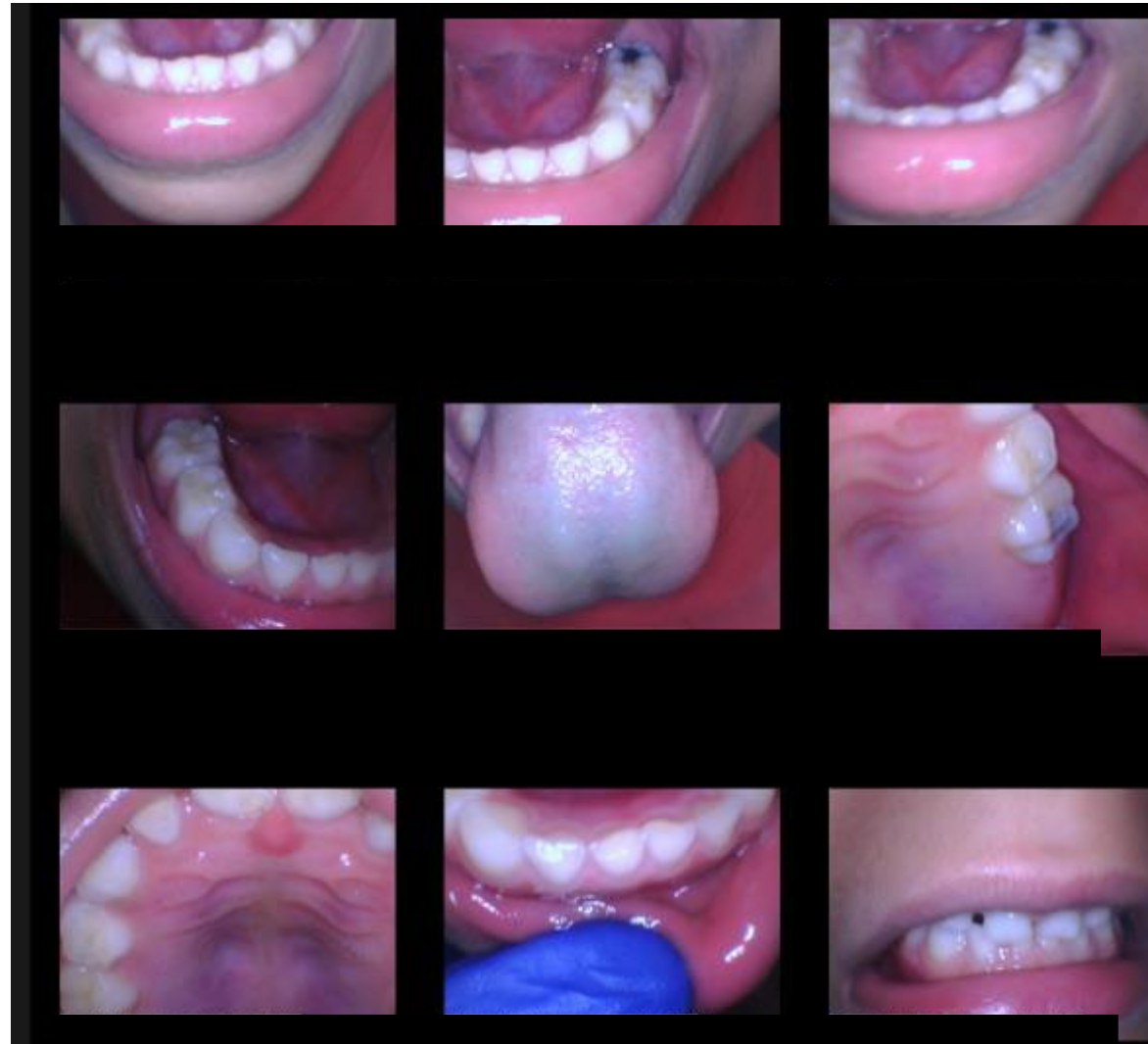Radiographs:



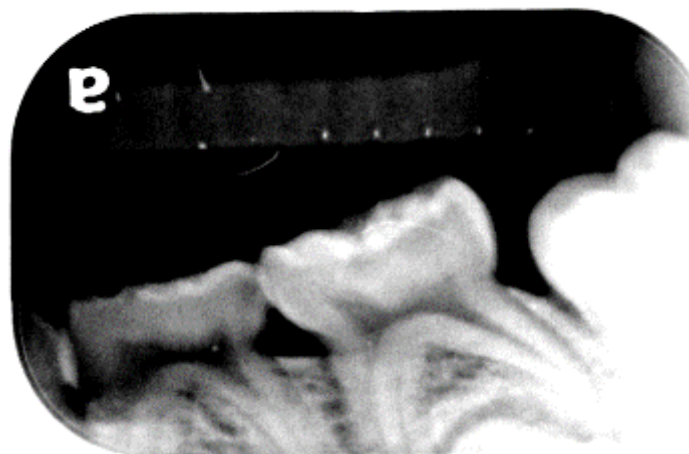
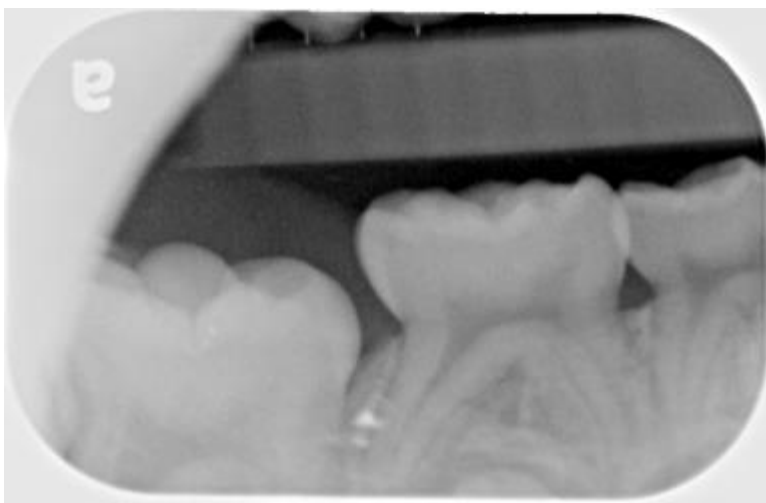
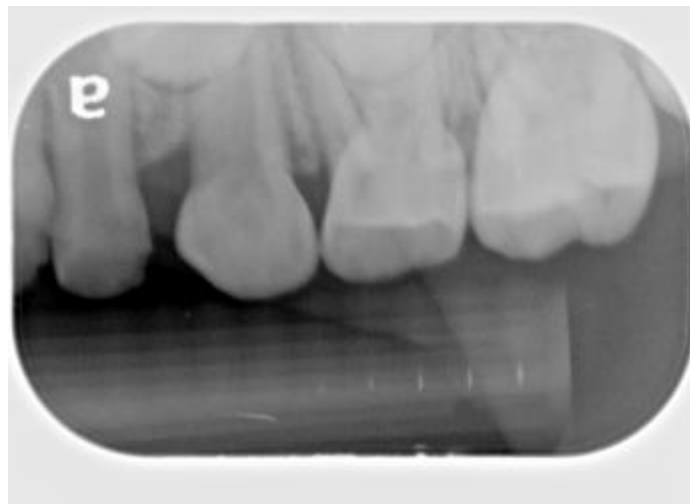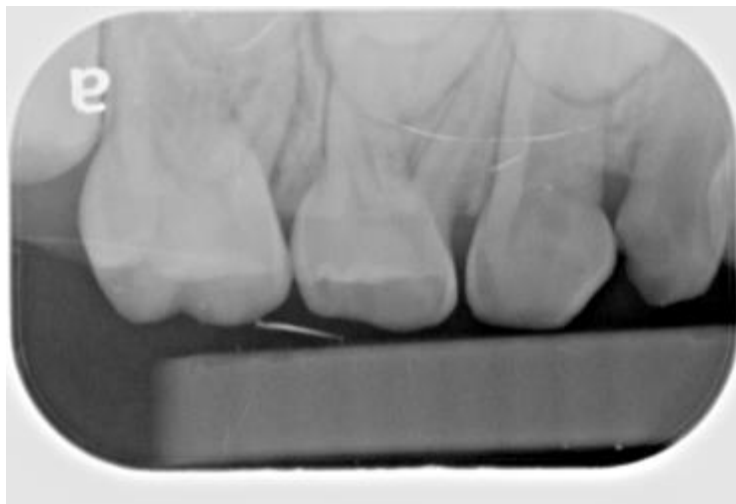
Recare...

- Recall on 3/2023
 - Unable to take x-rays; arrested caries on the teeth that SDF was applied to and found new incipient lesions
- Recall on 9/2023
 - After 2 popsicles obtained INTRAORAL photos; patient was standing and watching the screen as photos taken

Intraoral Photos: 9/12/2023



Radiographs:



Treatment under Sedation

Completed in-office sedation (dental school setting)

- tooth L had a stainless steel placed
- tooth K (occ) resin placed
- SDF was effective on tooth J (no tx at this time)

- RECALL DUE IN SEPT 2024

Case 3

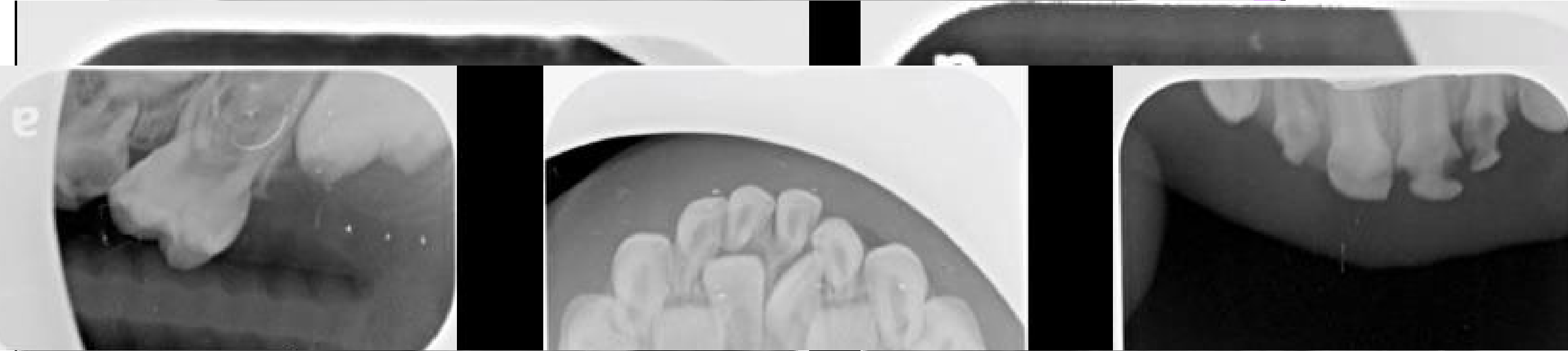
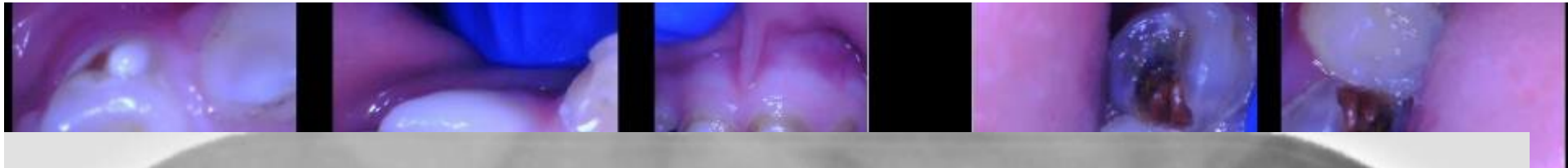Review of medical & dental history

MEDICAL

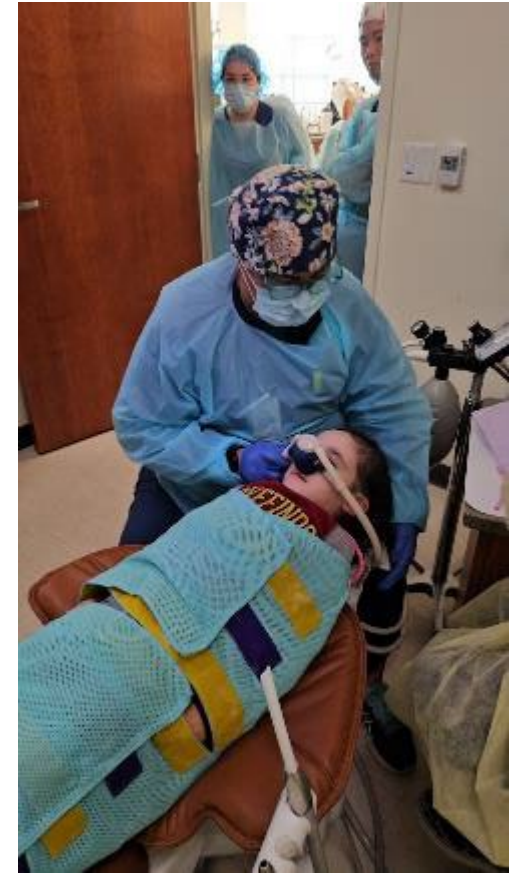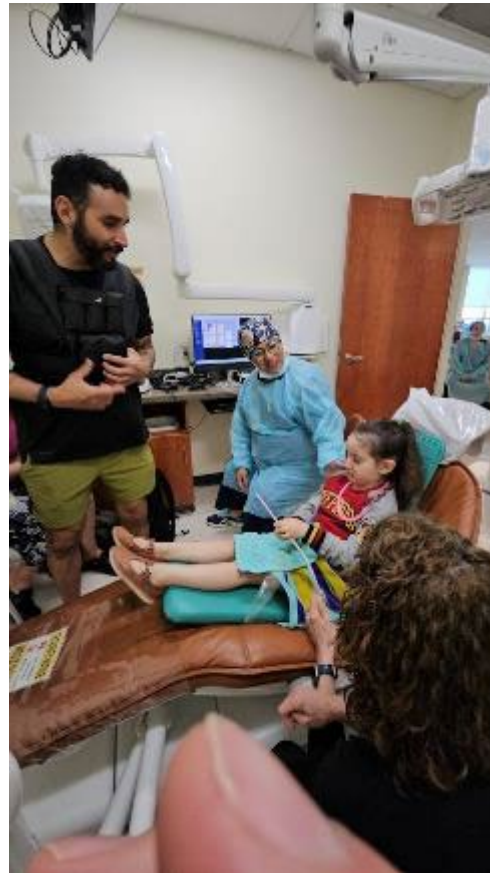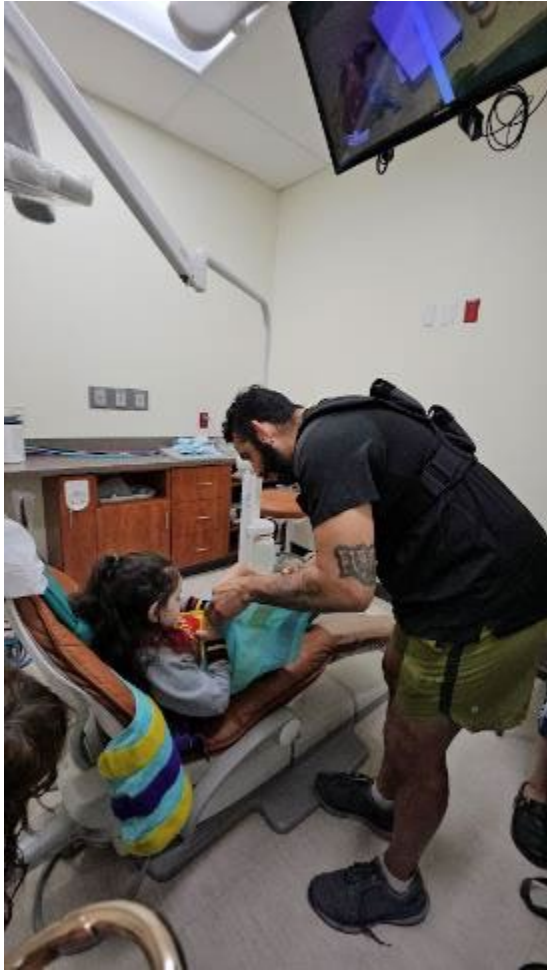- ASA 2
 - Autistic: unknown level
 - On target for
- Meds
 - none
- Other:
 - Speech therapy, PT (also for pelvic PT- due to holding urination), evaluating GI

DENTAL

- Visit on 2/2024 for initial evaluation/ another opinion
 - On abx; abscess present tooth B
 - Options presented
 - Elected papoose/nitrous/extraction of B & popsicle
 - Also got intraoral pics/ some xrays
- Comprehensive exam on 3/2024
 - Patient sat in chair, on top of papoose and wrapped herself
 - Able to get x-rays



Words from a parent with an Autistic Child



- <https://www.sotx.org/come-a-volunteer>

Statewide Events

Find your local competitions



SPECIAL OLYMPICS TEXAS

2024 Summer Games

San Antonio - Texas

May 16, 2024 - May 19, 2024



2024 Fall Classic

Midland-Odessa - Texas

October 03, 2024 - October 05, 2024

Questions

