

# Case Presentation

Dr. Dayl T Chachappan BDS MPH



UT Health  
San Antonio

# Meet Matias...

5-year old Matias presents to the clinic with his mother

Chief concern: “ My son has been in pain for **3 days**. I noticed a **swelling yesterday** in the upper back tooth area. His **eating and drinking habits** are **unaffected**. His sleep is **uninterrupted**.”

Matias rates the pain as a **6 out of 10**.

Does this situation merit antibiotics?



# More about Matias...

## Medical History

**ASA 2 (Obese (BMI:18.0))**

Non-contributory

No allergies

## Vitals

**Temp: 98.6° F**

P: 111bpm

Respiration Rate: 20 breaths/min

B/P: 102/65mmHg

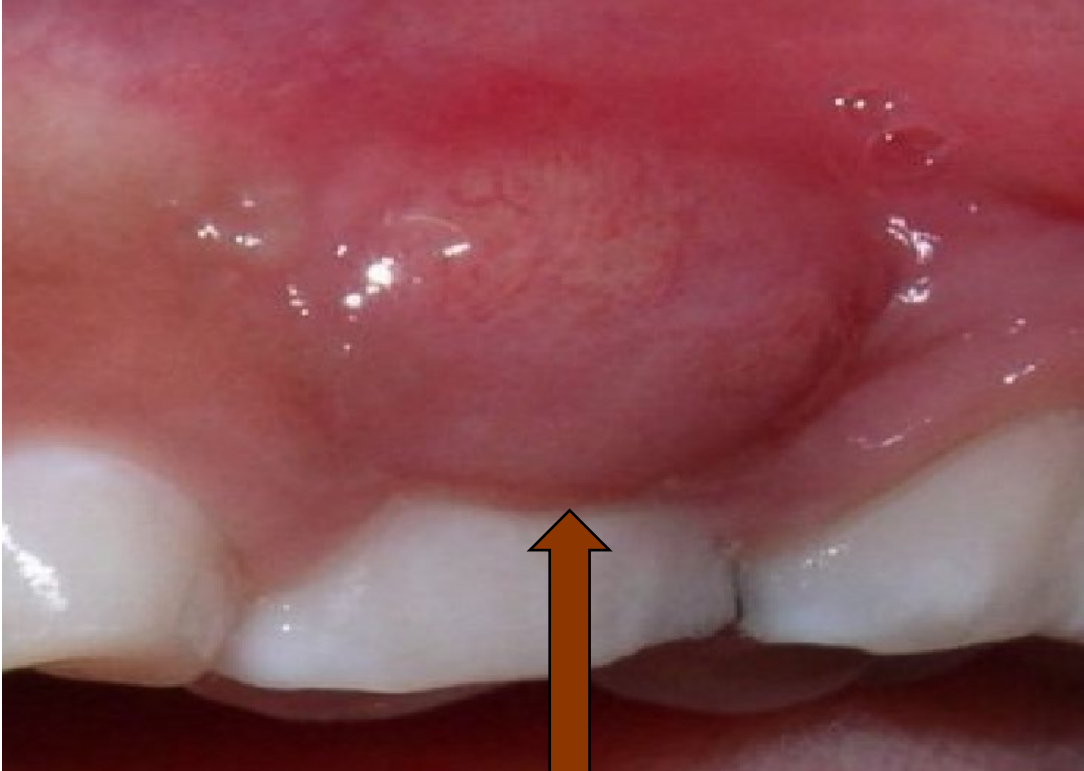## Social History

attends appointments with mother.

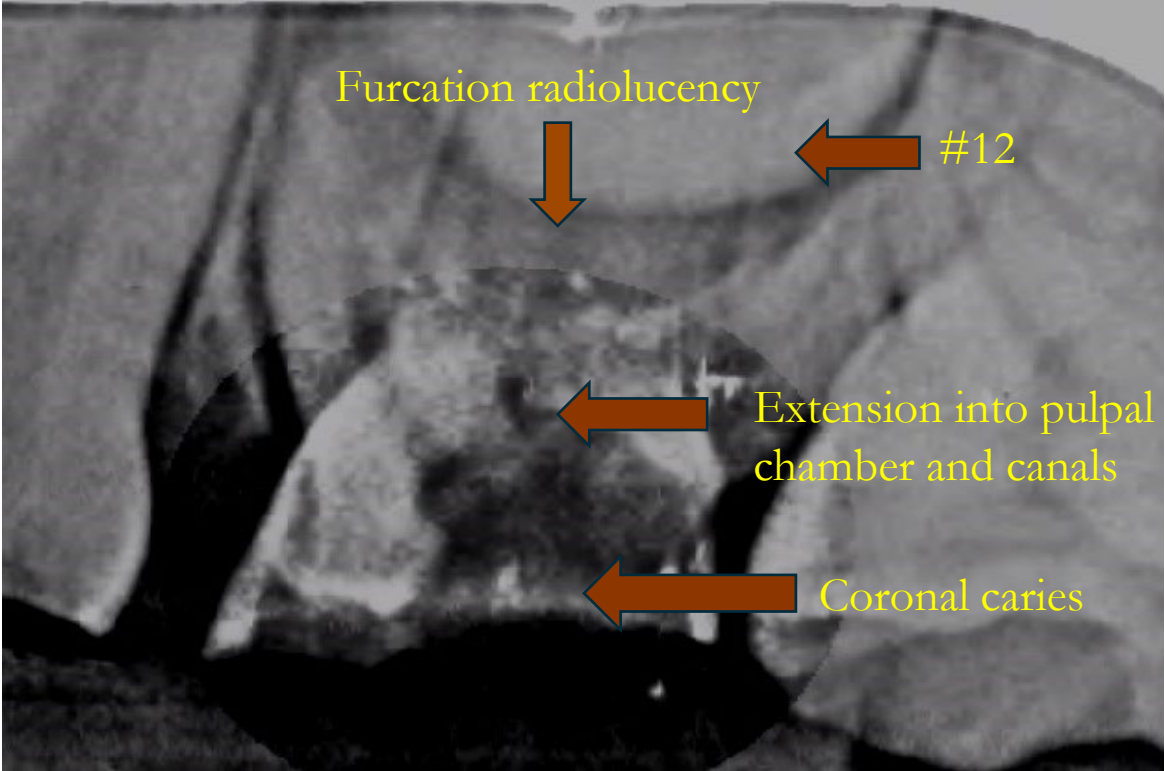
Self-Pay; no insurance

Extensive history of failed and cancelled appointments.

# The antagonist...



Abscess




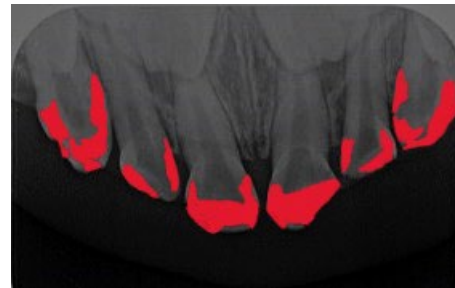
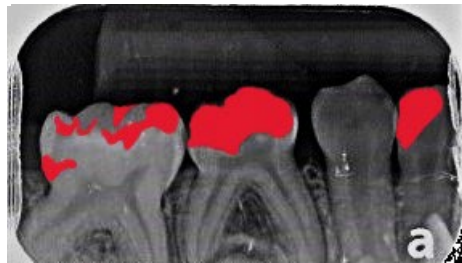
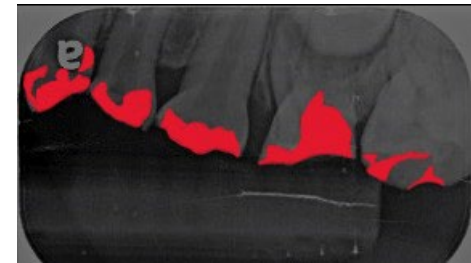
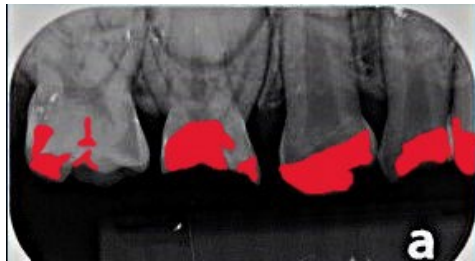
Furcation radiolucency

#12

Extension into pulpal chamber and canals

Coronal caries

# The plot thickens...



# Diagnostic road map...

	<u>Percussion</u>	<u>Palpation</u>	<u>Pulpal response</u>	<u>Mateo`s response</u>
#H	Normal	Normal	Normal	“Doesn`t hurt”
#I	<i>Positive</i>	<i>Positive</i>	<i>No response to heat/cold</i>	<i>“hurts the most”</i>
#J	Normal	Normal	Normal	“ doesn`t hurt”

	<u>Radiographs</u>	<u>Swelling type</u>	<u>Diagnosis</u>
#I	Periapical view <i>Periapical radiolucency, indicating periapical pathology</i>	<i>Localized</i>	<i>Pulpal diagnosis: <b>Pulp Necrosis (#I)</b></i> <i>Periapical diagnosis: <b>Acute apical abscess with buccal space infection</b></i>

# The back story...

## Reason for visit

08/29/2022:

### Initial exam

Referral from  
CentroMed at age 3.

09/21/2023:

### Recall exam

08/29/2024:

### Emergency visit

## Recommendations

Airway assessment: not a candidate  
for in-office sedation.

GA/FMDR due to ECC and young  
age.

Anticipatory guidance: weaning  
bottle feeding at night

GA/FMDR recommended

Mother declined

Emergency plan: Treatment with  
Nitrous oxide

#I extraction

Comprehensive re-evaluation  
for treatment

## Treatment provided

SDF applied on carious lesions.

SDF applied on carious lesions.

#I extracted with Nitrous  
oxide



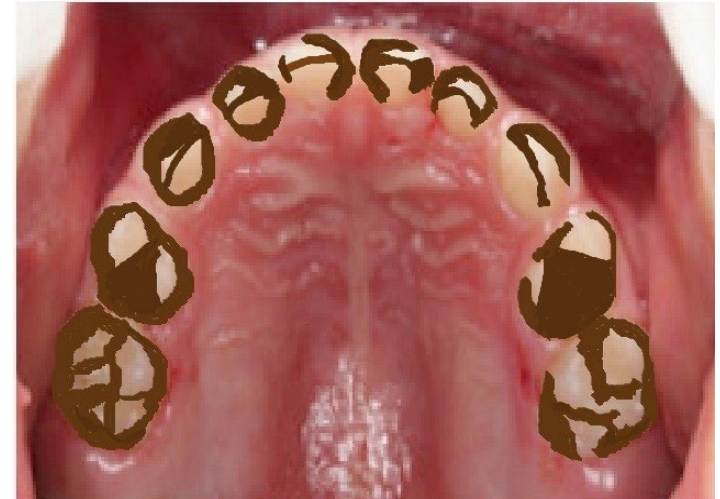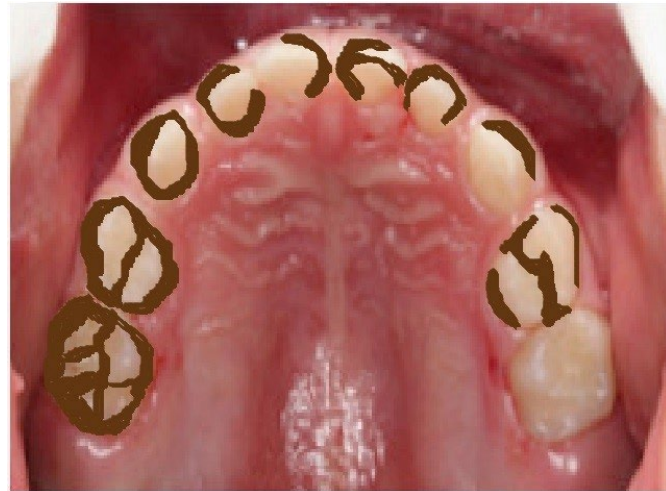
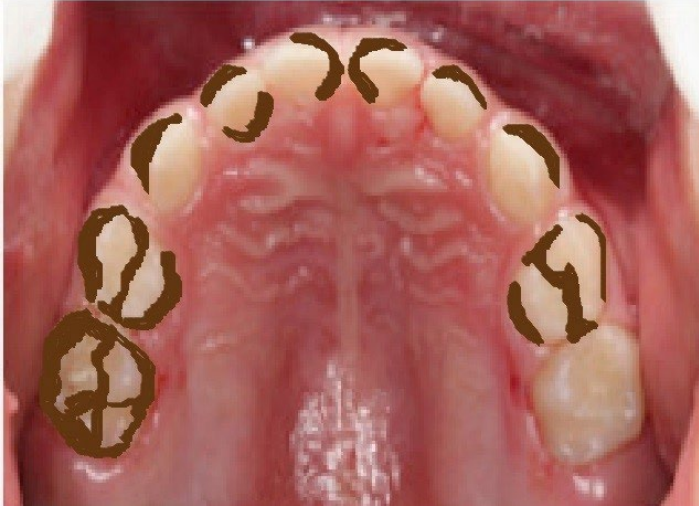
# Dramatic recreation of the past...

Visit 1

Year 1

Year 2

Code **blue!!**(#I)



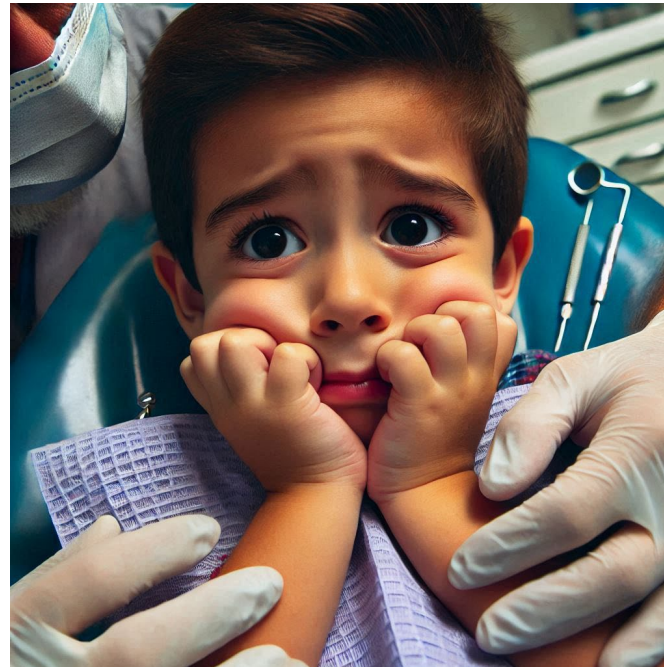
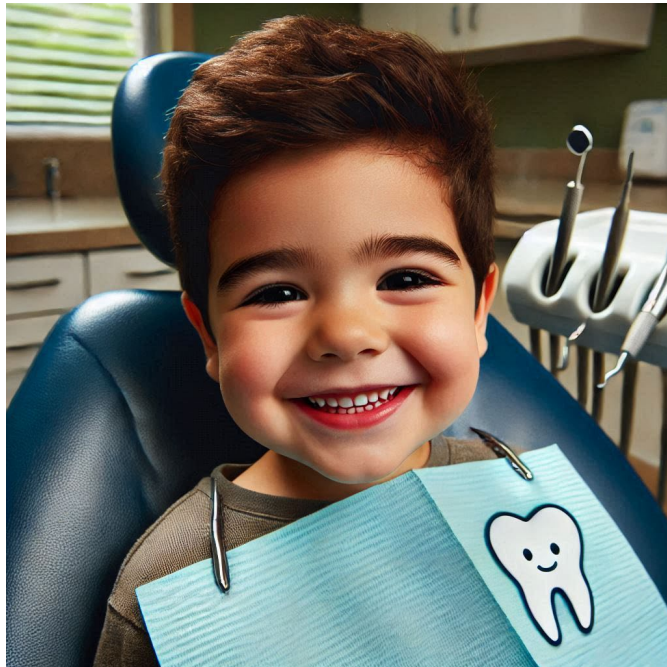
# The perfect **storm**

How it started...

v/s

....How it ended



# AAPD best practices

## Decision check list

- Signs of systemic involvement
  - Facial swelling
  - Fever
  - Difficulty breathing or swallowing
- Odontogenic origin
- Progressive
- Localized

## Other considerations

- Regular appointments
- Compliance with treatment

# AAPD best practices

## Decision check list

Signs of systemic involvement

Factors

Localized

**IMMEDIATE SURGICAL INTERVENTION**

## Problem list

Facial swelling on left side  
Vestibular abscess on #1  
Dental anxiety

## Goals

Reduce swelling, prevent spread  
Remove underlying cause  
Alleviate pain and discomfort

### Secondary goals:

Prevent recurrence  
Build trust for future treatment

## Options

Extraction

~~Prescribe antibiotics\*~~

\*American Dental Association. ACE Panel Report: Antibiotic Use in Endodontic Infections. 2019. [https://www.ada.org/-/media/project/ada-organization/ada/ada-org/files/resources/research/ace/ace-panel-report\\_antibiotic-use-in-endodontic-infections\\_final.pdf](https://www.ada.org/-/media/project/ada-organization/ada/ada-org/files/resources/research/ace/ace-panel-report_antibiotic-use-in-endodontic-infections_final.pdf). Accessed December 21, 2022

# The Imperfect trio....



## The next day...

Mom: “ *The school called and said that my son was vomiting and spiking a fever.*”

She later reported that her son did not have a fever when she picked him up and so will not be bringing him.

## It`s me. Hi, am I the problem?

*Was there systemic involvement?*

*Did I miss something?*

*Did I underestimate the extent/severity of systemic involvement?*

**Temp: 98.6° F**

P: 111bpm



Thank you for your attention!

Special thanks to Dr. Teemar Carey



UT Health

San Antonio